

Under the auspice of International Commission of Occupational Health Scientific Committee on Cardiology in Occupational Health



THE 7th ICOH INTERNATIONAL CONFERENCE ON WORK ENVIRONMENT AND CARDIOVASCULAR DISEASES

Bridging the gap between knowledge and preventive interventions
at the workplace to reduce cardiovascular diseases.

MAY 3-5, 2017 - Varese, Italy

Mario Kough

Alberto Molteni, MD

Humanitas Research Hospital, Internal Medicine and Syncope Unit, Department of
Biomedical Sciences, Humanitas University, Rozzano. Italy

May 3rd 2017

The case...

- Mario, 46 yrs of age. German plumber for a social cooperative
- Wakes up at 7.30
- Works with a helper for lifting weights
- No exposure to noxious inhalants
- Alcohol: 1 glass of wine during lunch and dinner



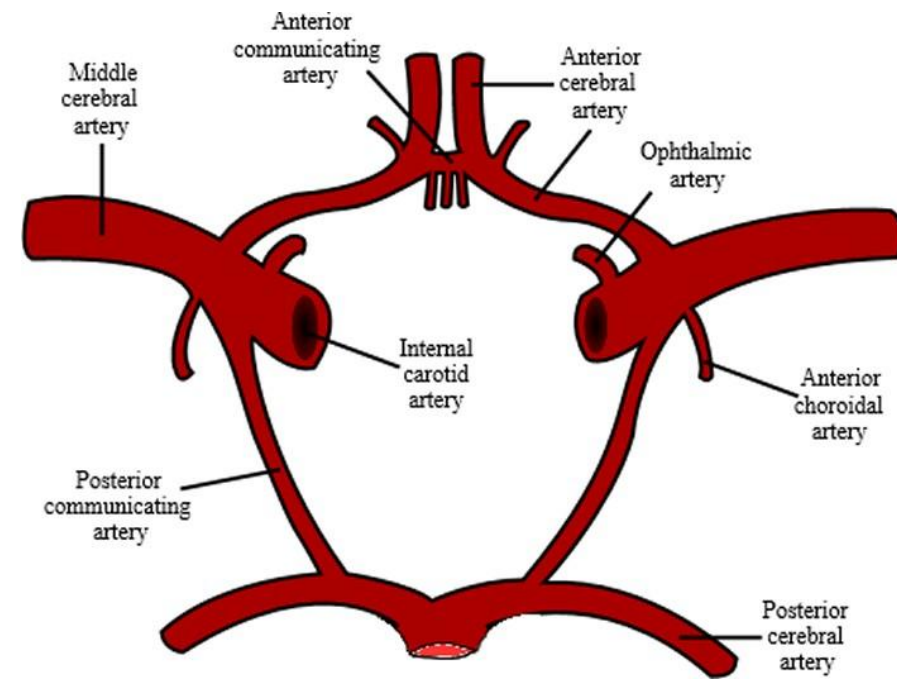
Past medical history

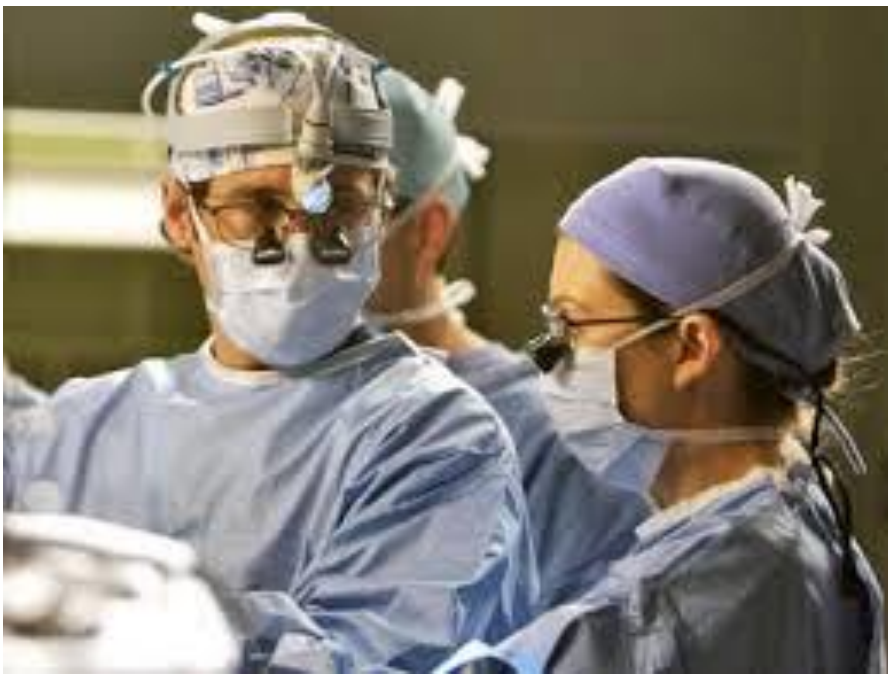- Hypertension. Treatment: amlodipine 10 mg die.

In 2002...

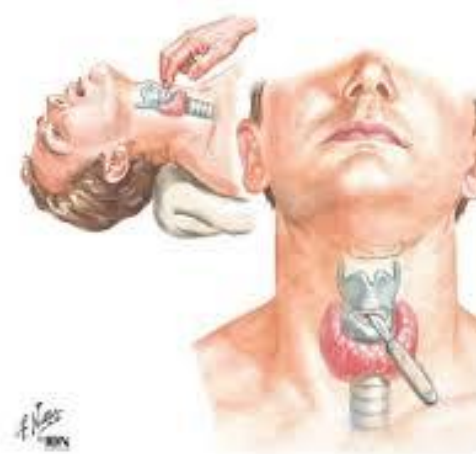

...Rupture of an aneurism of the anterior communicating artery





During neuro-surgical procedure, was necessary to perform a **tracheostomy**, due to difficult airways intubation



Surgery outcomes:

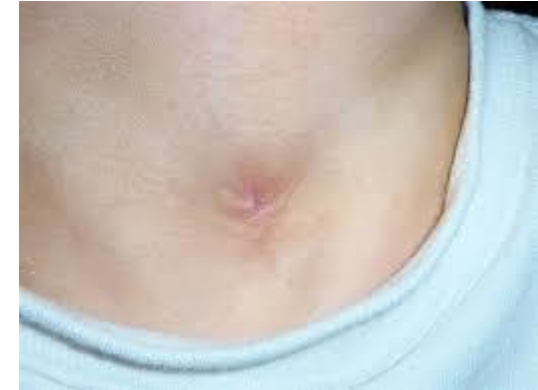- 1) Patient alive → cognitive- behavioural deficit with lack of inhibition (esp. verbal)
- 2) Patient reports «severe discomfort» at the level of the trachea, worsened by altered emotional state...

And...



3) ...and episodes of continuous cough, occasionally associated with episodes of loss of consciousness

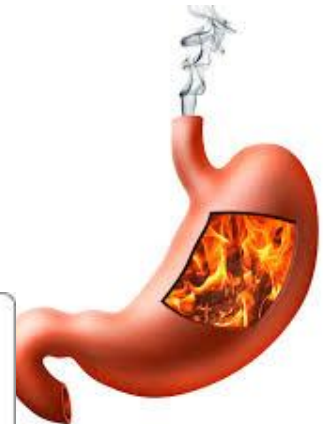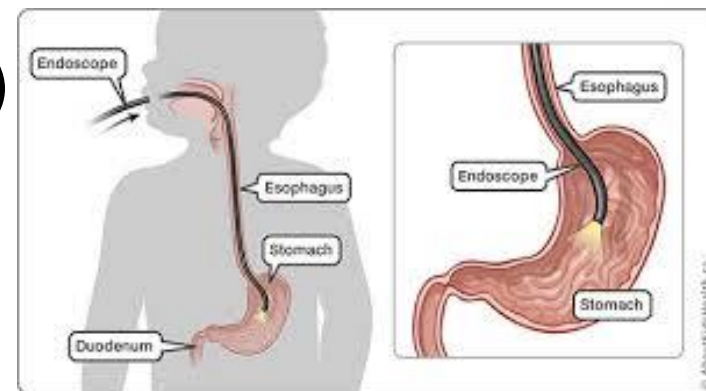
→ (no further exams performed)



During the hospitalization

-Endoscopy with diagnosis of Gastro Esophageal Reflux (GERD)

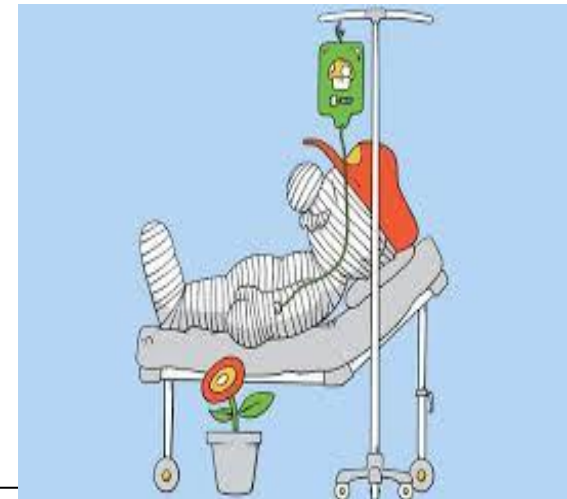→ started Proton Pump Inhibitors





In 2015 → new hospitalization:

Head concussion due to car accident
caused by a referred (witness) episode of loss
of consciousness.





Which exams would **YOU** perform?



Tests performed

- Physical exam
- 12 leads ECG
- Blood tests
- Head CT
- EEG
- Holter 24hr
- Heart ultrasound
- Sovra-aortic vessels US



Tests performed

ALL NEGATIVE.

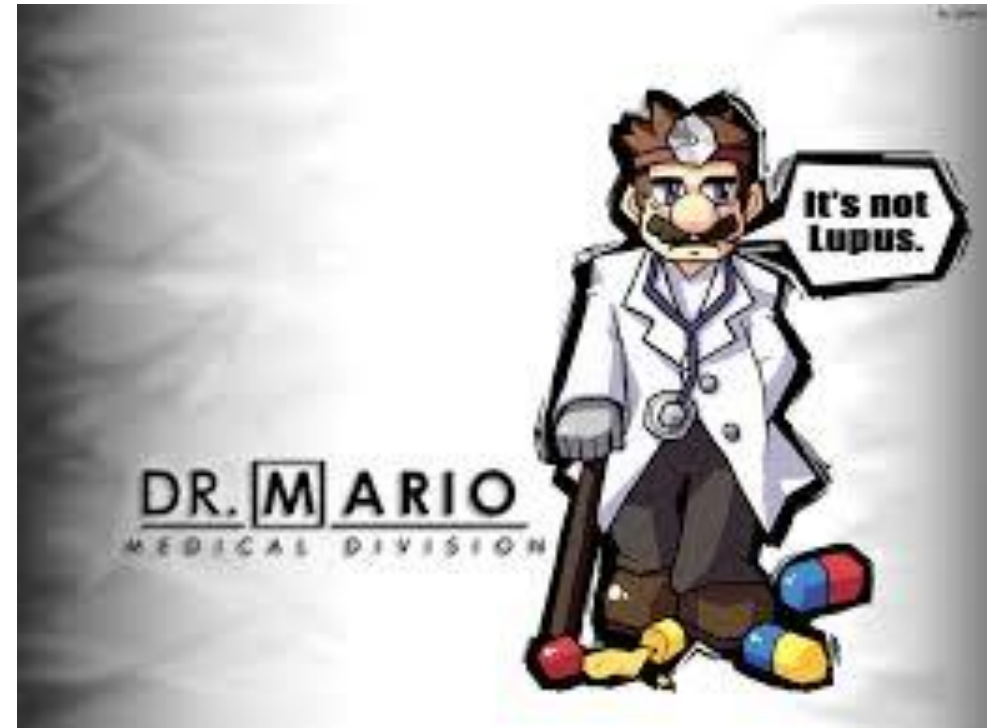Discharged



Is that it...?

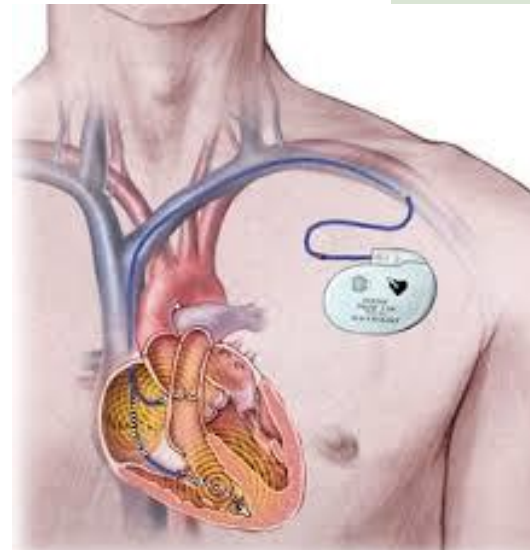
In march 2016, during a 24hr
ECG recording
prescribed by his family
Doctor for syncope recurrences*:
documented pathological
sinus pauses (4-6 seconds,
asymptomatic)

...WHAT WOULD **YOU** DO?



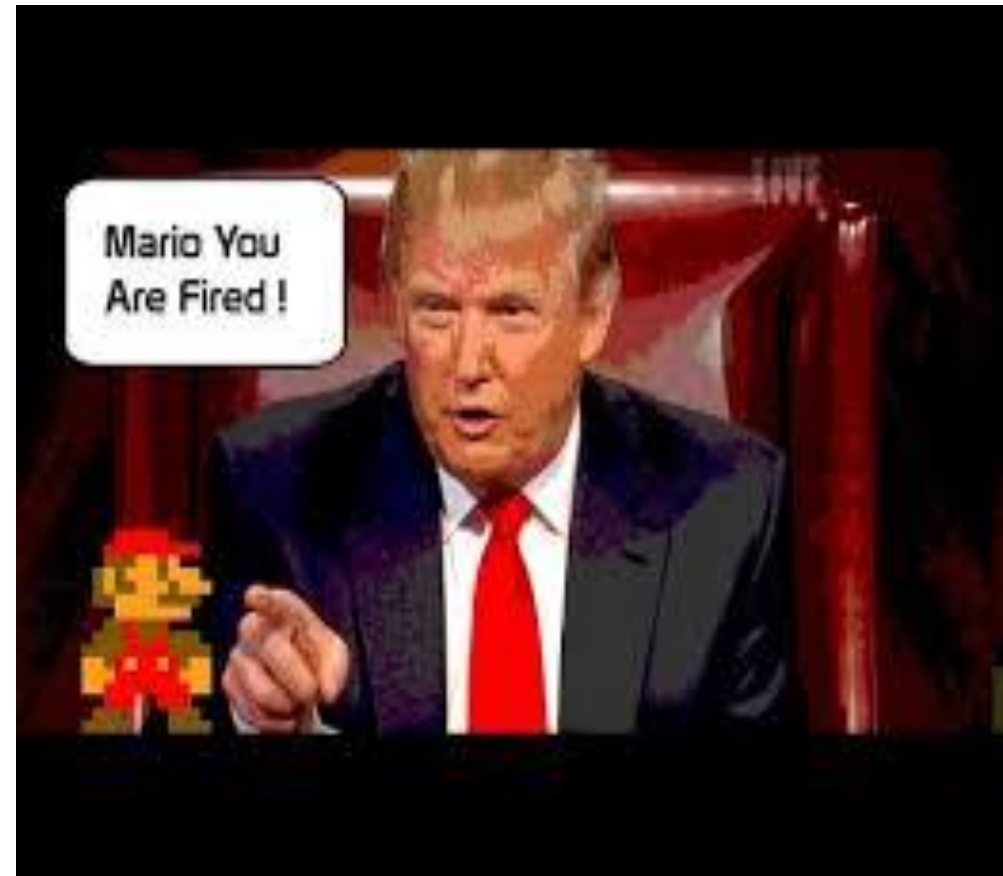

- Dual-chamber pace maker implant
- Borderline indications → loss of Consciousness (not documented)
- Despite it....






- The syncope episodes didn't stop
- Increasing sense of inadequacy → depressive crisis
- Loss in productivity: fired by his company



Here we are...



- Mario came to our Unit sent by a cardiologist of another hospital who followed him for the PM...

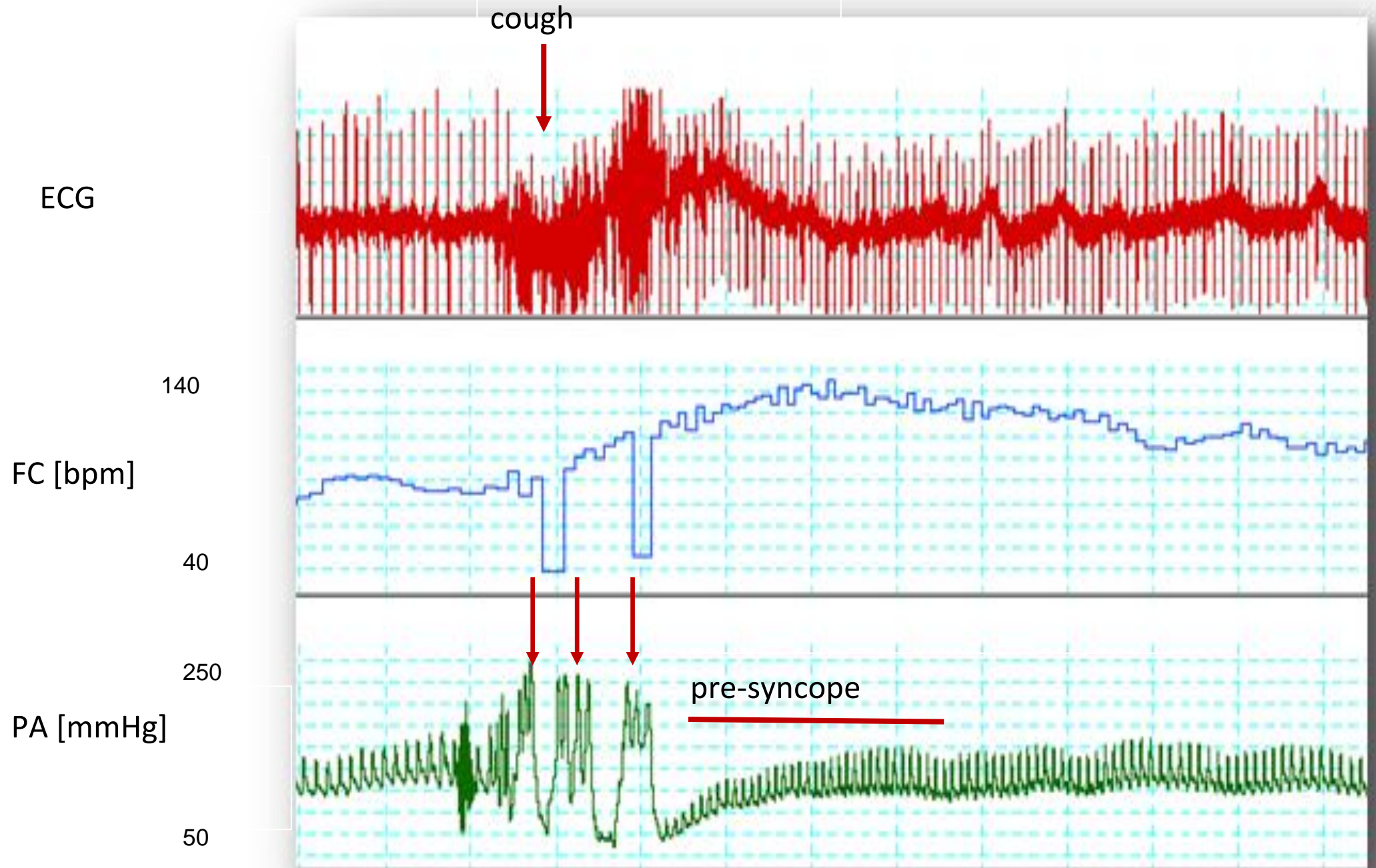
What was done...

Detail history taking → correlation of the syncope episodes with cough

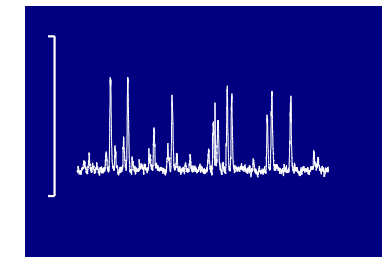
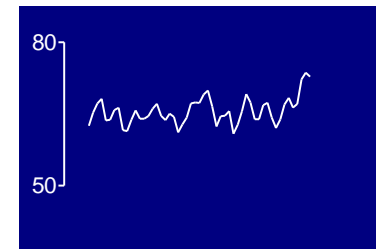
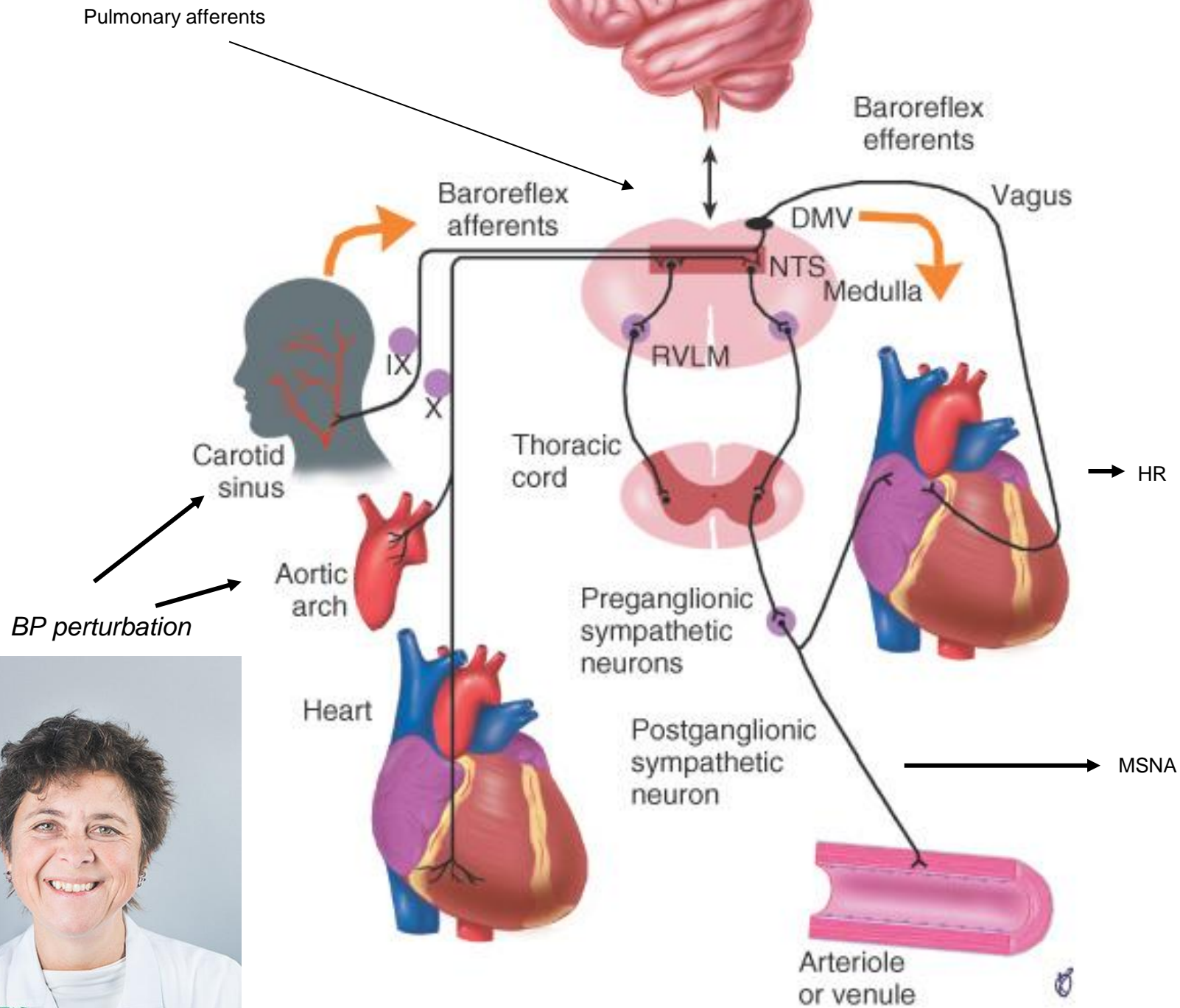
Tailored diagnostic path: Tilt test with reproduction of hypothesized mechanism → Cough



Mario: Orthostatic test 14.10.13



You now know this by heart...



Back to Mario...

- We identified the trigger
- We proved that cough was responsible for pre-syncope and likely for syncope episodes
- We are on the right path to make Mario go back to his life and work...



Therapy

- Treatment of trigger_{1,2} :
 - Proton pump inhibitors → VS GERD
 - Codeine → VS cough

1. Kusuyama T et al. J Cardiol 2009; 54(2):300-3
2. Whims LA et al. J Am Osteopath Assoc 1998; 98(3):170-2



♥♥♥♥♥ Happy end! ♥♥♥♥♥

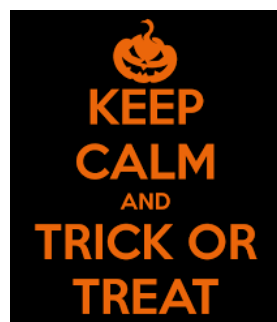- Mario was able to go back to his social and working life
- His follow up continues
- He has now his own enterpreurship of plumbers



Take home messages

- Detailed history taking is fundamental (SUSPECT!)
- Importance of reproducing the hypothesized stimulus under continuous monitoring of BP and HR

- *Treat the trigger*



Under the auspice of International Commission of Occupational Health Scientific Committee on Cardiology in Occupational Health

THE 7th ICOH INTERNATIONAL CONFERENCE ON WORK ENVIRONMENT AND CARDIOVASCULAR DISEASES

Bridging the gap between knowledge and preventive interventions
at the workplace to reduce cardiovascular diseases.

MAY 3-5, 2017 - Varese, Italy



***Mario Kough or
Cough it...and pass out***
Thank you for the attention

And special thanks to
Prof. Raffaello Furlan
Doctor Franca Barbic
Doctor Franca Dipaola

Alberto Molteni, MD

